

Class II Correction with the Invisalign System

WERNER SCHUPP, DDS
JULIA HAUBRICH, DDS
IRIS NEUMANN, DDS

The Invisalign* system has long been used to treat mild to moderate crowding, spacing, and tipped teeth.¹⁻⁵ Recently, it has been used successfully in more complex cases, such as those involving extractions, open bite, and Class II malocclusion.⁶⁻¹⁰

This article describes treatment of a unilateral Class II malocclusion with Invisalign and elastics, as well as a second Class II case treated with the Carrière Distalizer** followed by Invisalign appliances.

Case 1

A 14-year-old female presented with a Class I relationship on the right side and a Class II relationship on the left (Fig. 1). The treatment plan included Invisalign treatment with direct-bonded

attachments on the maxillary right canine, the mandibular left canine and premolars, and the mandibular right canine and premolars. Elastic hooks were also bonded to the maxillary left canine and mandibular left first molar (Fig. 2). We planned to align both arches using interproximal reduction (IPR), to distalize the upper left segment into a full Class I relationship, and to intrude the lower anterior teeth to reduce the overbite (Fig. 3).

In the first phase of treatment, the maxillary left buccal segment was distalized into a full Class I relationship, as was the maxillary right canine. For better anchorage, the patient wore Class II

*Registered trademark of Align Technology, Inc., 881 Martin Ave., Santa Clara, CA 95050; www.aligntech.com.

**Registered trademark of ClassOne Orthodontics, 5064 50th St., Lubbock, TX 79414; www.classoneortho.com.

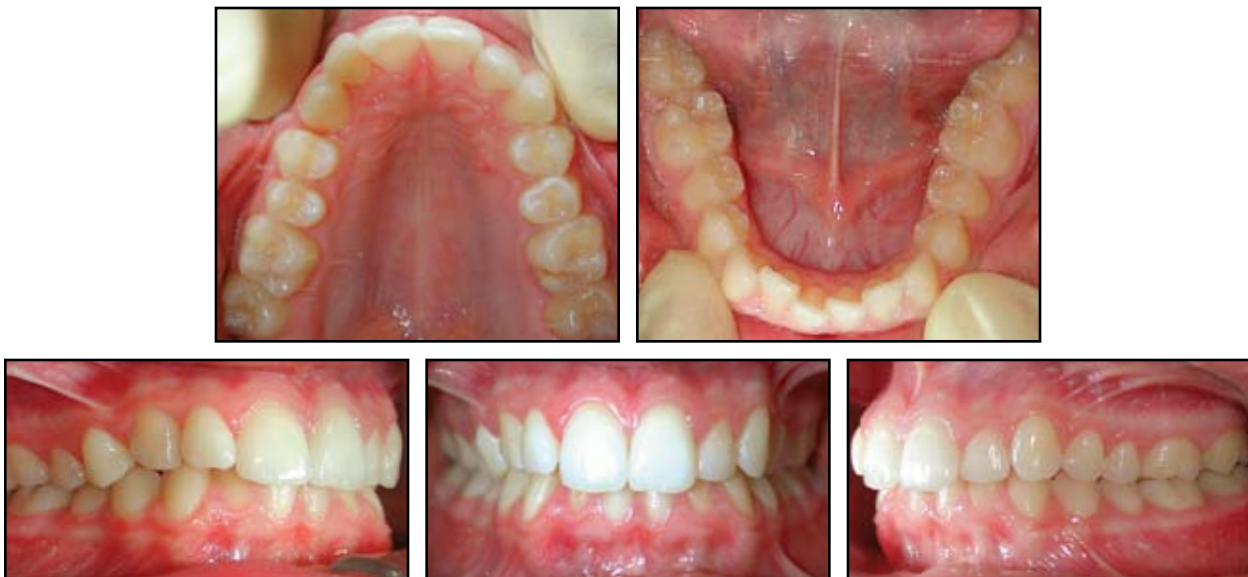

Fig. 1 Case 1. 14-year-old female with Class II occlusion on left, Class I occlusion on right, crowding in both arches, midline deviation, and deep bite before treatment.

The authors are in the private practice of orthodontics at Hauptstrasse 50, 50996 Köln, Germany. Dr. Schupp is Visiting Professor, Department of Orthodontics, University of Ferrara, Italy. Drs. Schupp and Haubrich are members of Align Technology's Clinical Education Council. E-mail Dr. Schupp at praxis@schupp-ortho.de.



Dr. Schupp



Dr. Haubrich



Dr. Neumann

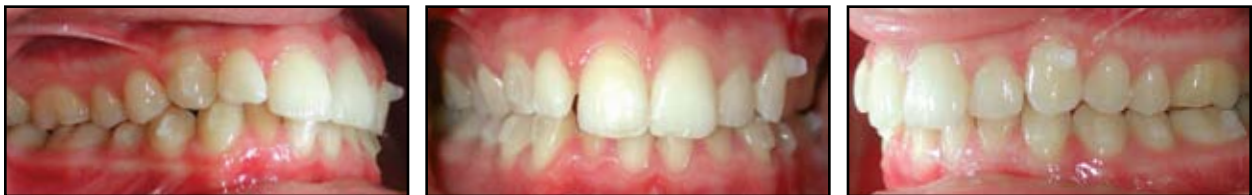
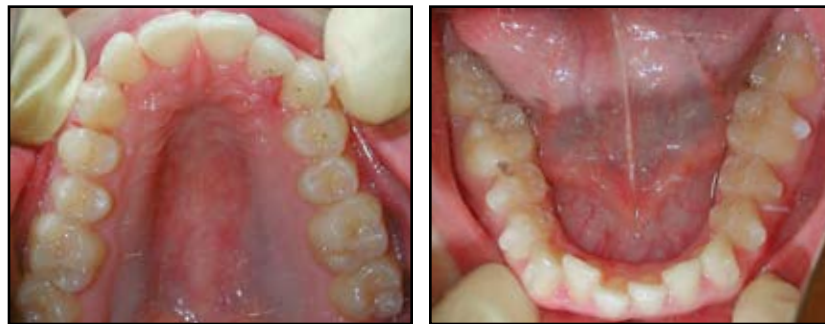
Fig. 2 Case 1. Direct-bonded attachments on maxillary right canine, mandibular left canine and premolars, and mandibular right canine and premolars, with hooks for Class II elastics bonded to maxillary left canine and mandibular left first molar.

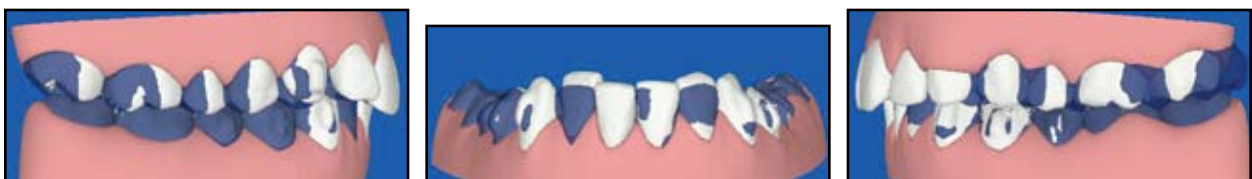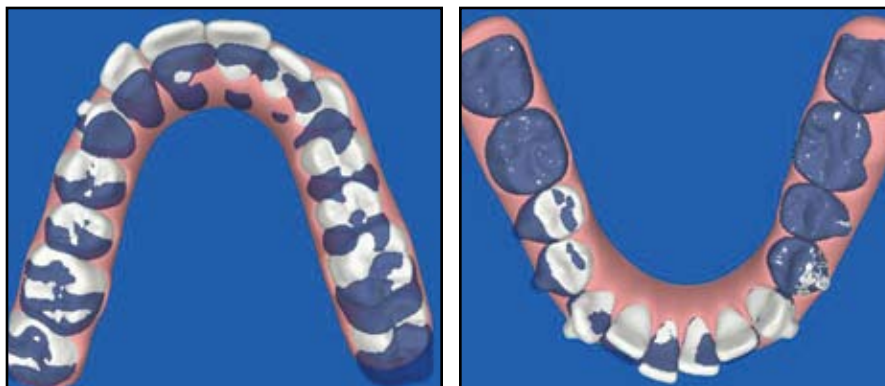


Fig. 3 Case 1. ClinCheck* treatment goals (in blue): Class I occlusion on both sides, upper molar distalization, alignment of both arches, and intrusion of lower incisors to reduce deep bite.

elastics on the left side throughout distalization ($\frac{1}{8}$ " medium, 4oz). IPR was performed on the lower incisors, which were then intruded. The hooks on the maxillary left canine and mandibular left first molar were then removed. To extrude the posterior segments into full intercuspation, additional attachments were bonded to the maxillary right first premolar and first and second molars, the maxillary left premolars and first and second molars, and the mandibular left and right first and second molars, and new impressions were taken for case refinement (Fig. 4). The plan for refine-

ment was to extrude all posterior teeth to obtain full occlusal contact, as seen in the ClinCheck projection (Fig. 5).

After 23 months, the treatment goals had been achieved. The results were maintained with removable Impreton*** retainers. Final ClinCheck projections matched the post-treatment results exactly (Figs. 6,7), and the panoramic x-ray taken after treatment showed no pathology.

***Registered trademark of Scheu Dental GmbH, Am Burgberg 20, 58642 Iserlohn, Germany; www.scheu-dental.com.

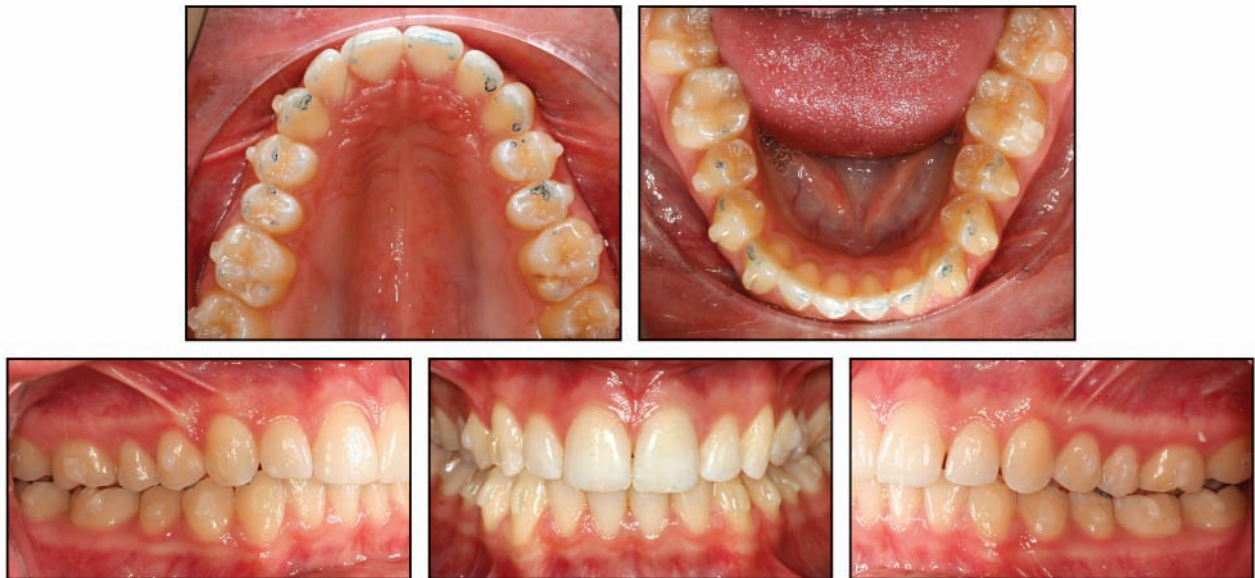

Fig. 4 Case 1. Start of case refinement. Note blue contact points missing on molars. To extrude posterior segments, additional vertical rectangular attachments bonded to maxillary right first premolar and first and second molars, maxillary left premolars and first and second molars, and mandibular first and second molars.

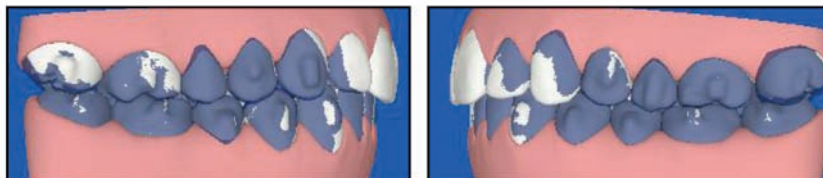


Fig. 5 Case 1. ClinCheck projection at start of case refinement, showing extrusion of both posterior segments to obtain full occlusal contact.

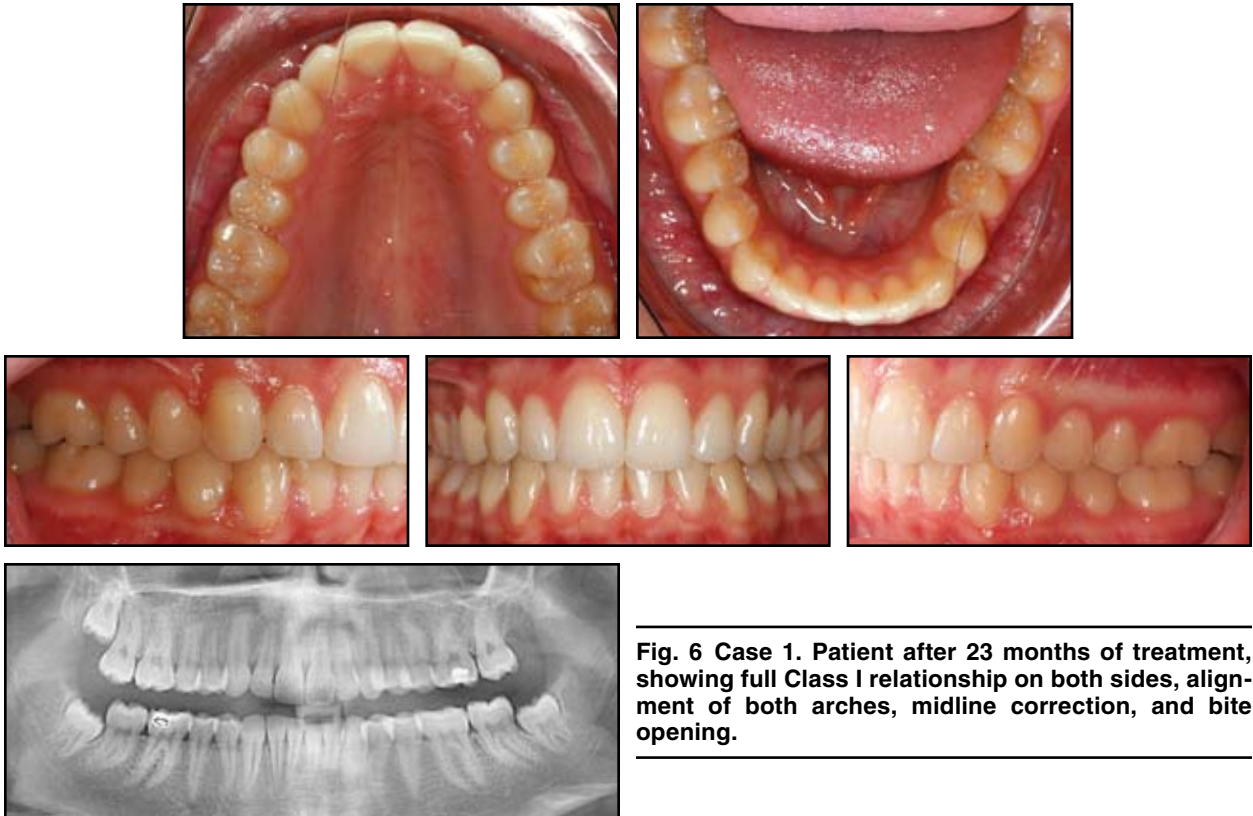


Fig. 6 Case 1. Patient after 23 months of treatment, showing full Class I relationship on both sides, alignment of both arches, midline correction, and bite opening.

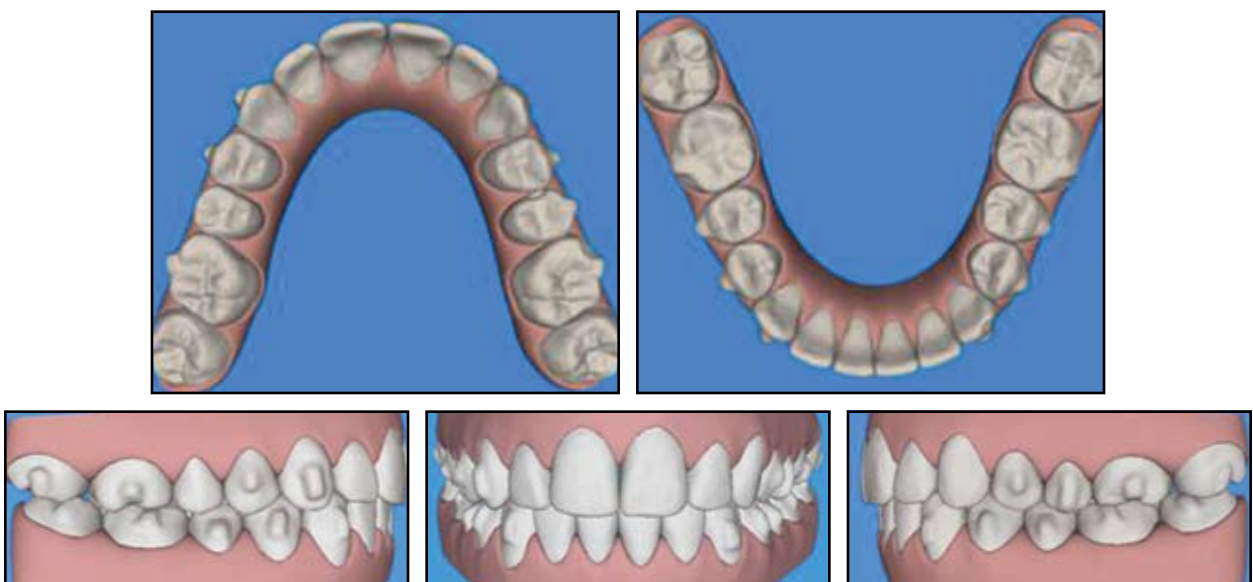


Fig. 7 Case 1. ClinCheck post-treatment projection, matching clinical results.

Class II Correction with the Invisalign System

Case 2

A 14-year-old male presented with a Class II malocclusion on the right and a slight malocclusion on the left, a midline deviation, and crowding in

the upper and lower anterior regions (Fig. 8). To resolve the Class II relationship, the treatment plan included pretreatment with the Carrière Distalizer on both sides. The patient wore Class II elastics ($\frac{3}{16}$ " medium, 4oz) from the distalizer on both

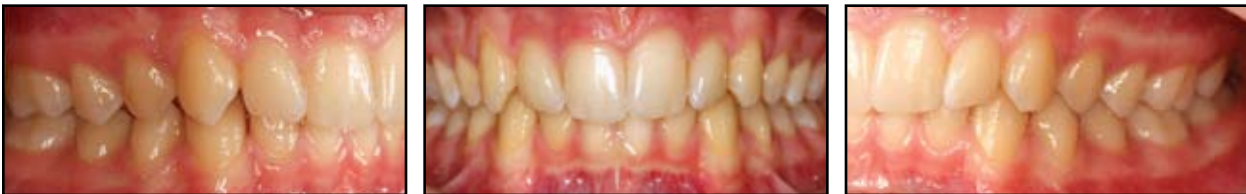
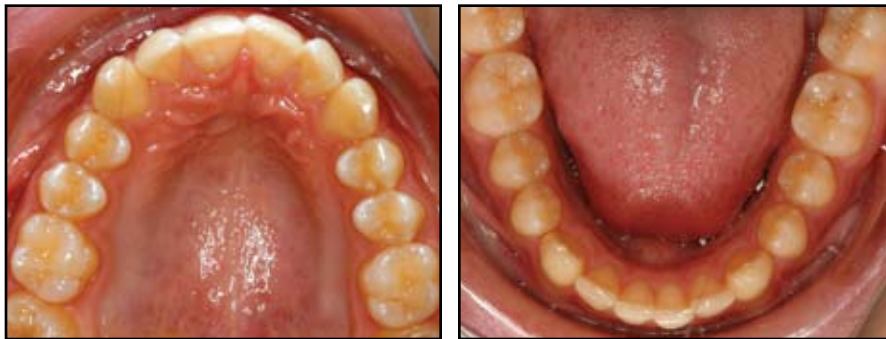
Fig. 8 Case 2. 14-year-old male with bilateral Class II relationship, midline deviation, and deep bite before treatment.

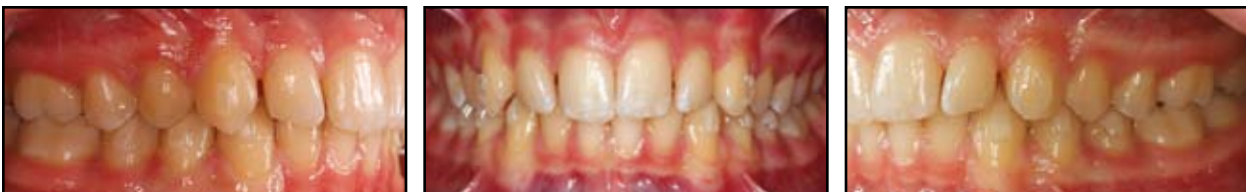
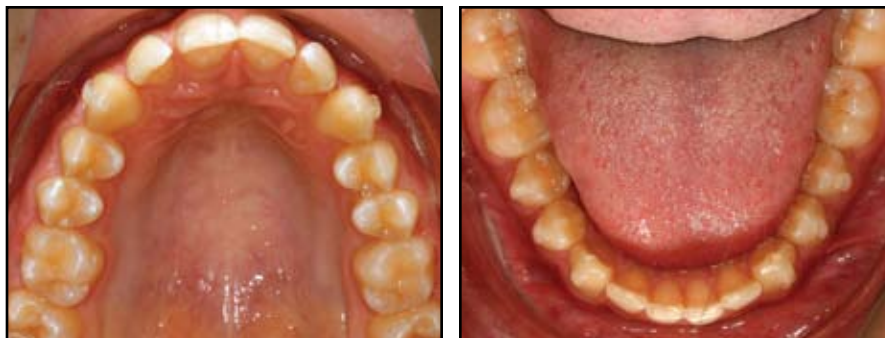
Fig. 9 Case 2. Full Class I relationship achieved in four months of pretreatment with Carrière Distalizer; start of Invisalign treatment with direct-bonded attachments on maxillary canines and mandibular canines and premolars.

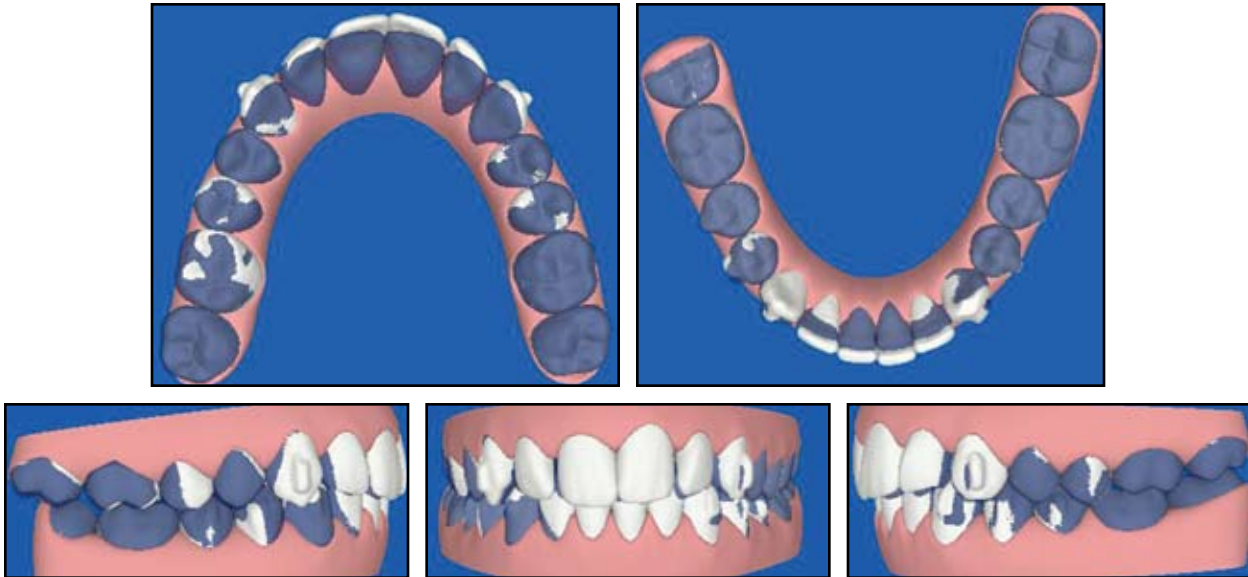


Fig. 10 Case 2. ClinCheck superimpositions with treatment goals (in blue): Class I relationship, alignment of both arches, and functional overjet and overbite.

canines to a fixed partial lower appliance with hooks distal to the mandibular first molars.

After four months, spaces had opened up distal to the maxillary lateral incisors, and a full Class I relationship had been achieved on both sides (Fig. 9). The distalizers were then removed, and attachments were bonded to the maxillary canines and the mandibular canines and premolars. The treatment plan was to obtain a full Class I relationship on both sides, align the upper and lower incisors, and achieve a functional overjet and overbite (Fig. 10). Because the patient was not wearing Class II elastics for retention, we began case refinement by bonding additional elastic hooks to the maxillary right canine and mandibular right first molar (Fig. 11).

The combination of the distalizer pretreatment with Invisalign therapy reduced the treatment time compared with Invisalign treatment alone. After 10 months of Invisalign treatment, a complete Class I relationship had been achieved on both sides, the upper and lower anterior teeth were aligned, and the midlines were corrected (Figs. 12,13). The final panoramic x-ray showed no pathology.

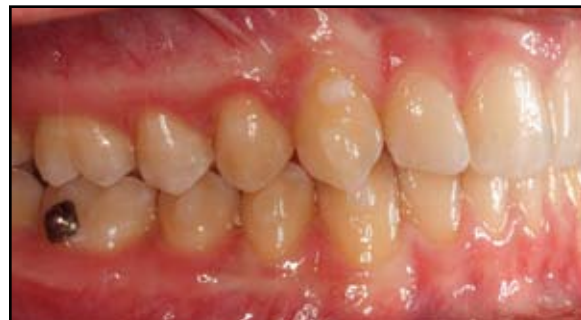

Fig. 11 Case 2. Vertical rectangular attachment on maxillary right canine, with hooks on maxillary right canine and mandibular right first molar for attachment of Class II elastics before case refinement.

Discussion

Distalization of maxillary molars using Invisalign appliances and Class II mechanics offers a comfortable, esthetic alternative for patients with Class II malocclusion. In our experience, the following considerations are important:

- Treatment of Class II patients with Invisalign is virtually impossible without additional elastic

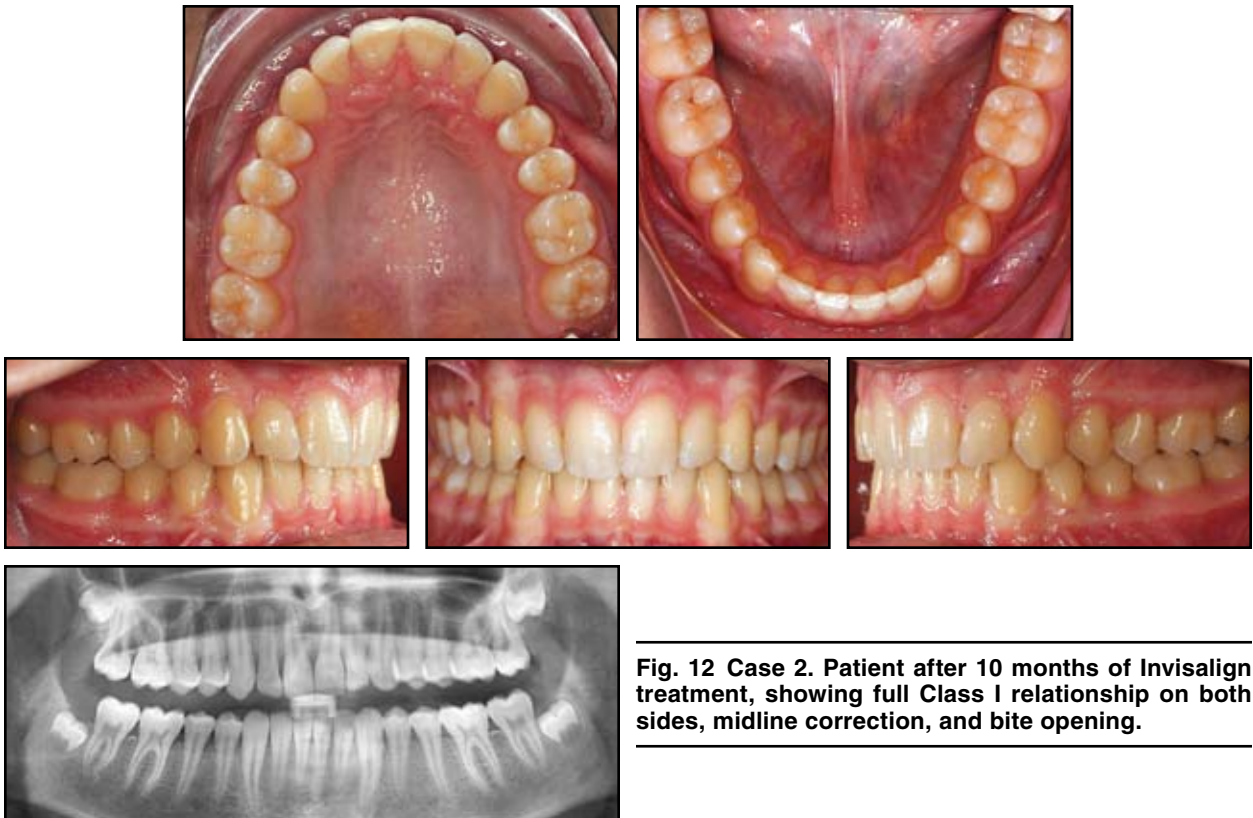


Fig. 12 Case 2. Patient after 10 months of Invisalign treatment, showing full Class I relationship on both sides, midline correction, and bite opening.

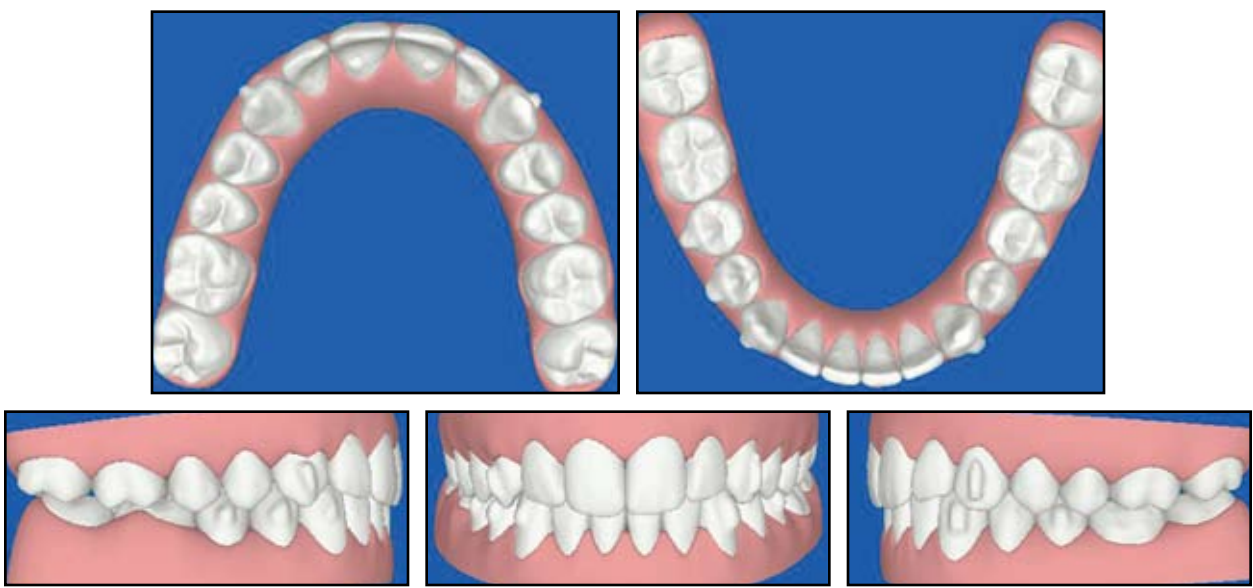


Fig. 13 Case 2. ClinCheck post-treatment projection, matching clinical results.

anchorage, which should be worn all night and for at least three hours during the day.

- Hooks should be bonded directly to the surfaces of the upper canines and lower first or second molars, not to the aligners, since the vertical (lifting) force of the elastics can easily dislodge the aligners.
- In addition to the elastic hooks on the maxillary canines, a vertical rectangular attachment is needed to avoid undesired rotations of these teeth (Fig. 14).
- Pretreatment use of a distalizer requires 22 hours of daily Class II elastic wear for anchorage. Either intramaxillary elastics can be worn to a mini-implant, or intermaxillary anchorage can be used. We suggest bonding a segmented arch directly to the lower molars and second premolars, with an elastic hook placed in the molar region (Fig. 15). The patient could also wear a removable splint for better retention.

REFERENCES

1. Boyd, R.L.; Miller, R.J.; and Vlaskalic, V.: The Invisalign system in adult orthodontics: Mild crowding and space closure cases, *J. Clin. Orthod.* 34:203-212, 2000.
2. Boyd, R.L. and Vlaskalic, V.: Three-dimensional diagnosis and orthodontic treatment of complex malocclusions with the Invisalign appliance, *Semin. Orthod.* 7:274-293, 2001.
3. Vlaskalic, V. and Boyd, R.L.: Orthodontic treatment of a mildly crowded malocclusion using the Invisalign system, *Austral. Orthod. J.* 17:41-46, 2001.
4. Bollen, A.M.; Huang, G.; King, G.; Jujoel, P.; and Ma, T.: Activation time and material stiffness of sequential removable orthodontic appliances, Part 1: Ability to complete treatment, *Am. J. Orthod.* 124:496-501, 2003.
5. Clements, K.M.; Bollen, A.M.; Huang, G.; King, G.; Jujoel, P.; and Ma, T.: Activation time and material stiffness of sequential removable orthodontic appliances, Part 2: Dental improvements, *Am. J. Orthod.* 124:502-508, 2003.
6. Womack, W.R.: Four-premolar extraction treatment with Invisalign, *J. Clin. Orthod.* 40:493-500, 2006.
7. Hönn, M. and Göz, G.: A premolar extraction case using the Invisalign system, *J. Orofac. Orthop.* 67:385-394, 2006.
8. Norris, R.A.; Brandt, D.J.; Crawford, C.J.; and Fallah, M.: Restorative and Invisalign: A new approach, *J. Esth. Restor. Dent.* 14:217-224, 2002.
9. Boyd, R.L.: Complex orthodontic treatment using a new protocol for the Invisalign appliance, *J. Clin. Orthod.* 41:525-547, 2007.
10. Boyd, R.L.: Esthetic orthodontic treatment using the Invisalign appliance for moderate to complex malocclusions, *J. Dent. Ed.* 72:948-967, 2008.

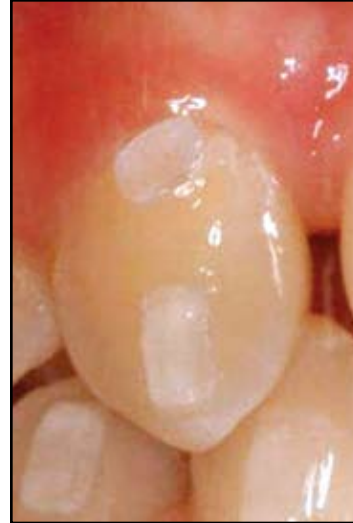

Fig. 14 Case 2. Vertical rectangular attachment placed on maxillary right canine, in addition to direct-bonded elastic hook, to avoid undesired rotation due to elastic force.

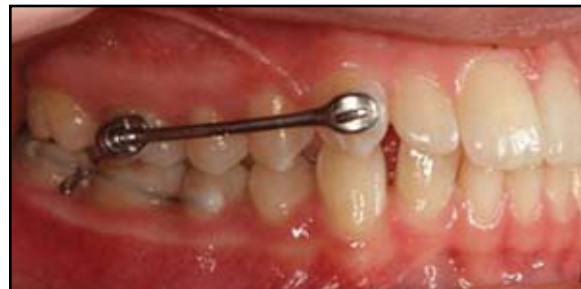

Fig. 15 Case 2. Carrière Distalizer bonded to maxillary right canine and first molar; fixed arch segment bonded to mandibular right second premolar and first and second molars, with elastic hook placed between molars.